



PATIENT PRESENTING CLINICAL SIGNS

Xena Rescue History: Grade4/6 murmur. Asymptomatic.
-Sedation used: Dex/torb

SPECIES ELECTROCARDIOGRAPHIC FINDINGS *Note: Single lead ECGs are evaluated as a rhythm strip. Morphology/MEA cannot be definitively commented on.

Canine A single lead ECG is available from an AliveCor monitor; 50mm/s, 20mm/mV. The average heart rate is 1115bpm (range 107-150bpm). The rhythm is sinus in origin, with a p for every QRS complex and vice versa. The P and QRS morphologies are positive with normal dimension. No ectopic beats, pauses or dysrhythmias observed.

BREED German Shepherd ECG diagnosis: Normal sinus rhythm with respiratory variation.

ECHOCARDIOGRAM FINDINGS

SEX 2D, m-mode, color flow and doppler imaging is available. The mitral valve is thickened without prolapse into the left atrial lumen. Trace mitral regurgitation. Mild left atrial enlargement. No LV dilation with adequate myocardial function. Mild LV hypertrophy (0.9cm). The endocardium appears fibrotic and remodeled. The papillary muscles are hyperechoic and hypertrophied. The tricuspid valve appears subjectively normal; however, trace tricuspid regurgitation is seen. Normal right atrial and ventricular diameter and morphology indicating no overt evidence of pulmonary arterial hypertension. The pulmonic valve is normal in morphology and mobility. Mildly increased pulmonic outflow velocities with laminar flow. No obvious pulmonic insufficiency. The aortic valve is trileaflet although thickening with decreased mobility. Sub-aortic narrowing is also visualized. Moderate aortic regurgitation seen. A small perimembranous VSD is visualized with left to right flow. Flow is seen crossing the defect in diastole as well as systole due to aortic insufficiency. No pericardial or pleural effusion noted.

INTERPRETED BY

Maggie Machen
Lamy, DVM, DACVIM
(Cardiology)

CARDIAC CHART

IMAGING PERFORMED BY

Rebekah Jakum, CVT
ARDMS/RVT

HOSPITAL NAME

New Britain VC

REFERRING VET

Dr. Bandekar

INVOICE

21168

DATE

9.22.2021

CANINE CARDIAC PARAMETERS	MR VMAX (m/s)	TR VMAX (m/s)	LA/AO (Boon method)	LA/AO (Heart Base; Swe)	FS (%)	EF (%)	EPSS (cm)
NORMAL PARAMETER	4.5-5.5	<2.7	1.3	<1.6	28-40	40-100	<0.6
PATIENT	NA	2.3	NM	1.3	43	76	0.16
CANINE CARDIAC PARAMETERS	HR (BPM)	AV VMAX (m/s)	PV MAX (m/s)	BODY WEIGHT (kg)	LA 2D short axis Base view (cm)	LVIDd Avg; 2D and m-mode short axis (cm)	LVIDs Avg; 2D and m-mode short axis (cm)
NORMAL PARAMETER	50-100	0.7-1.7	0.7-1.6	BELOW	BELOW	BELOW	BELOW
PATIENT	NM	5.7	1.7	6.3	2.1	2.0	1.3
*Normal chamber parameters expressed as a mean value				3	1.27	2.46	1.36
BODY WEIGHT DEPENDENT PARAMETERS							
*Note: All measurements based upon multi-modal images and methods. An average value is reported.							
Adapted from June Boon, Veterinary Echocardiography, 1998				5	1.40	2.74	1.60
Rishniw M and Hollis NE, J Vet Intern Med 2000; 14:429-435				10	1.50	3.27	2.06
Hansson et al, Vet Rad and Ultrasound 2002				15	1.83	3.71	2.43
Bonagura et al. Echocardiography: principles of				20	2.02	4.14	2.80
				25	2.18	4.48	3.10
				30	2.33	4.83	3.39
				35	2.48	5.17	3.69
				40	2.62	5.48	3.96
				50	2.88	6.07	4.46



PATIENT INTERPRETATION OF THE FINDINGS & FURTHER RECOMMENDATIONS

Xena Rescue

SPECIES

Canine

BREED

German Shepherd

SEX

Female

AGE

2 months

WEIGHT

13.8 lbs

INTERPRETED BY

Maggie Machen
 Lamy, DVM, DACVIM
 (Cardiology)

IMAGING PERFORMED BY

Rebekah Jakum, CVT
 ARDMS/RVT

HOSPITAL NAME

New Britain VC

REFERRING VET

Dr. Bandekar

INVOICE

21168

DATE

9.22.2021

The cause of the murmur is severe aortic and sub-aortic stenosis (AS/SAS) causing significantly elevated blood flow velocity through the aortic valve. There is also a moderate leak in diastole. This is a congenital malformation of the aortic valve, leading to decreased excursion in systole. The LV walls are mildly increased in dimension indicating early pressure overload at a young age. There is also a significant amount of LV fibrosis present, which is what ultimately predisposes these cases to development of malignant arrhythmias. Trace TR is also noted, however is insignificant at this time. Finally, a small ventricular septal defect (VSD) is visualized which is of little comparative hemodynamic significance. It is, however, interesting that the aortic insufficiency can be seen crossing the defect as well, which is unusual and should be monitored. The remainder of the cardiac structure and function appears adequate. The ECG is unremarkable with a normal sinus rhythm.

It is worth noting that the **utilized sedation protocol is NOT recommended for echocardiography, as cardiac hemodynamics are significantly altered.** An alternative option is strongly recommended in the future.

In any complex congenital case referral to a local Cardiologist is strongly recommended for lifelong monitoring.

No surgical intervention is available at this time for this particular abnormality. Medical management through heart rate control is recommended as below, in hopes of decreasing the obstruction long term. That being said this should not be instituted in an asymptomatic 2-month-old dog and waiting until at 4-6 months is ideal. Omega fatty acid supplementation may be of some long term anti-arrhythmic benefit.

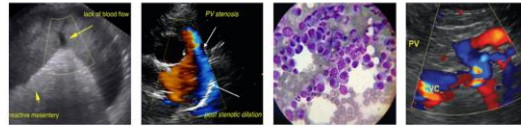
Prognosis is guarded yet highly variable, with many dogs in the severe category succumbing to malignant arrhythmias early in life and others maintaining asymptomatic status long term. Serial echocardiography is recommended lifelong to assess for progression and risk for complication. Monitor for development of labored breathing, exercise intolerance or collapse episodes, as AS patients are more predisposed to development of arrhythmias than to CHF. Moderate lifelong exercise restriction is advised.

Once Atenolol is initiated, anesthetic risk is mild if needed. Avoid heart rate stimulating drugs such as atropine or glycopyrrolate unless clinically indicated. Avoid ketamine and acepromazine due to systemic vascular effects. Mild IV fluid restriction is advised. Recommend prophylactic antibiotics for any orthopedic or dental procedure in the future given predisposition to endocarditis.

PLAN

Consider referral as discussed. If declined, once 4-6 months old, institute atenolol to effect: Initiate 6.25mg PO q12-24h and up-titrate to desired effect. Goal is to suppress heart rate <130bpm even with stress/activity. *Will likely have to increase as weight increases.

Recommend recheck echocardiogram in 6-12 months to screen for progression.



PATIENT

Xena Rescue

SPECIES

Canine

BREED

German Shepherd

SEX

Female

AGE

2 months

WEIGHT

13.8 lbs

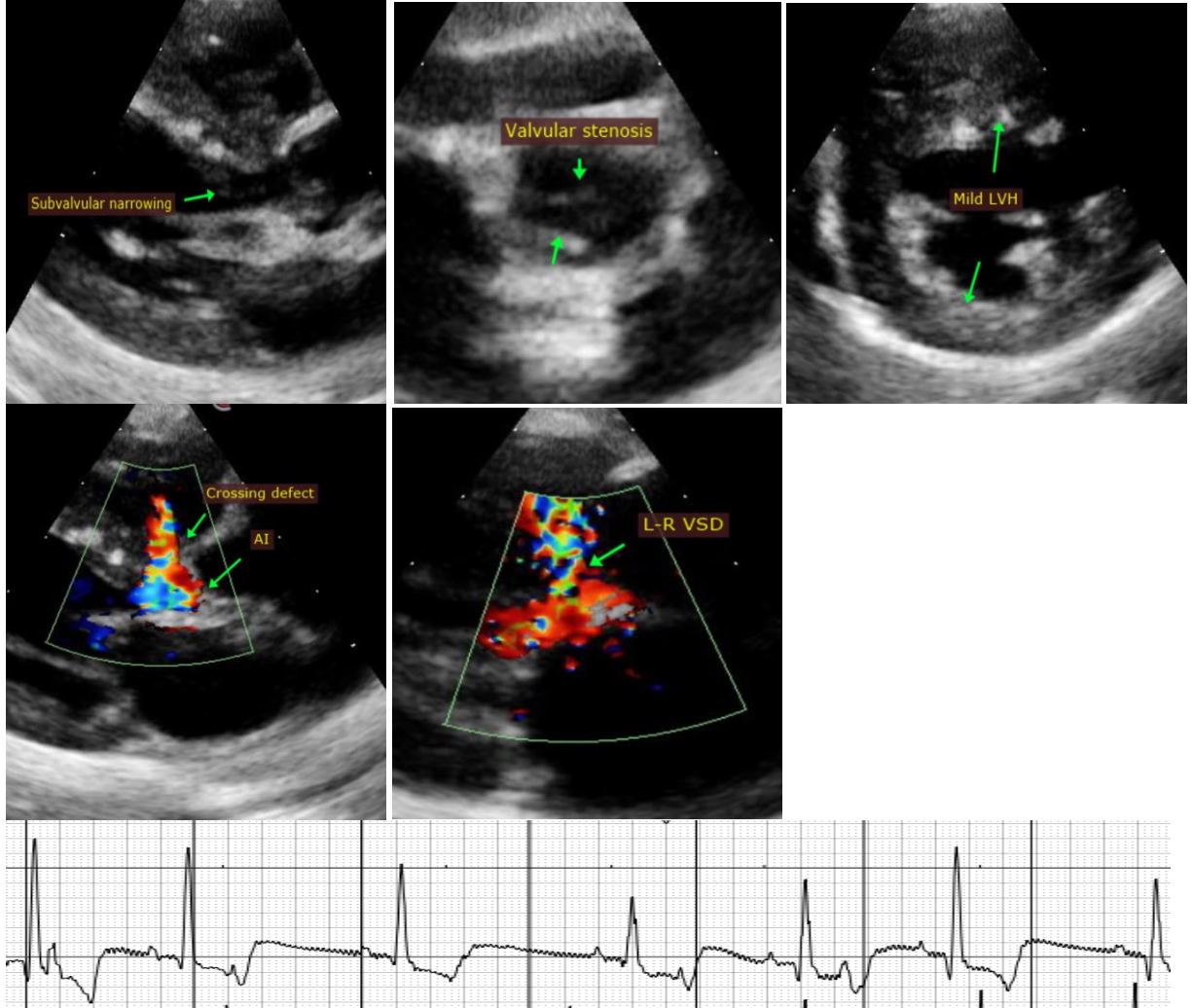
INTERPRETED BY

Maggie Machen Lamy, DVM, DACVIM (Cardiology)

IMAGING PERFORMED BY

Rebekah Jakum, CVT ARDMS/RVT

IMAGES



HOSPITAL NAME

New Britain VC

REFERRING VET

Dr. Bandekar

INVOICE

21168

DATE

9.22.2021

The information and recommendations provided are based on the images presented by the referring veterinarian. No evaluation can be communicated regarding pathology that was not visible in the image/video clips provided.

Thank you for this referral. If the clinical or image interpretation does not parallel your findings or if I can be of any further assistance, please contact me.

Maggie Machen Lamy, DVM
Diplomate of the American College of Veterinary Internal Medicine (Cardiology)
info@sonopath.com